

M R AMBEDKAR DENTAL COLLGE & HOPITAL

1/36 CLINE ROAD COOKE TOWN BANGALORE - 560005

DEPARTMENT OF PEDODONTICS

DEPARTMENT WISED AILY O. P. STATISTICS FOR THE MONTH OF MAY- 2026

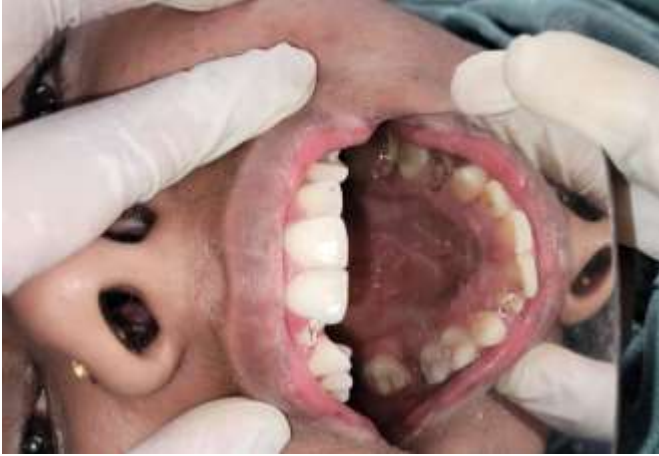SL NO	DATE	NEW PATIENTS	RE CALL PATIENTS	TOTAL PATIENTS
1	02.05.2026	13	19	32
2	04.05.2026	26	15	41
3	05.05.2026	22	25	47
4	06.05.2026	19	17	36
5	07.05.2029	18	22	40
6	08.05.2030	16	21	37
7	09.05.2031	21	15	36
8	11.05.2032	33	26	59
9	12.05.2033	17	26	43
10	13.05.2026	17	29	46
11	14.05.2026	28	23	51
12	15.05.2026	11	19	30
13	16.05.2026	10	26	36
14	18.05.2026	27	29	56
15	19.05.2026	15	29	44
16	20.05.2026	33	19	52
17	21.05.2026	26	18	44
18	22.05.2026	26	23	49
19	23.05.2026	22	28	50
20	25.05.2026	23	25	48
21	26.05.2026	18	24	42
22	27.05.2026	18	20	38
23	29.05.2026	25	12	37
24	30.05.2026	26	24	50
TOTAL		510	534	1044

**M R AMBEDKAR DENTAL COLLEGE AND HOSPITAL
BANGALORE**

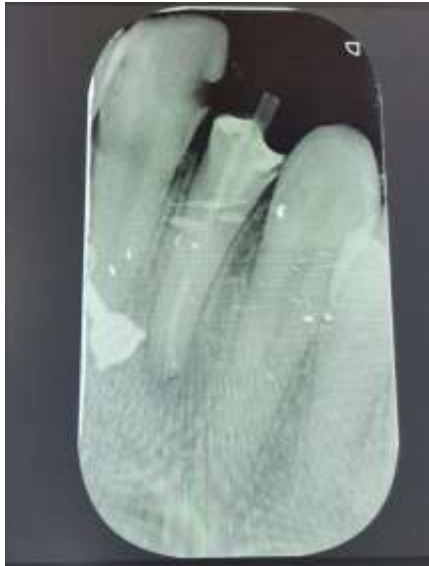**DEPARTMENT OF PEDODONTICS
AND PREVENTIVE DENTISTRY**

Fiber Optic Post And Core

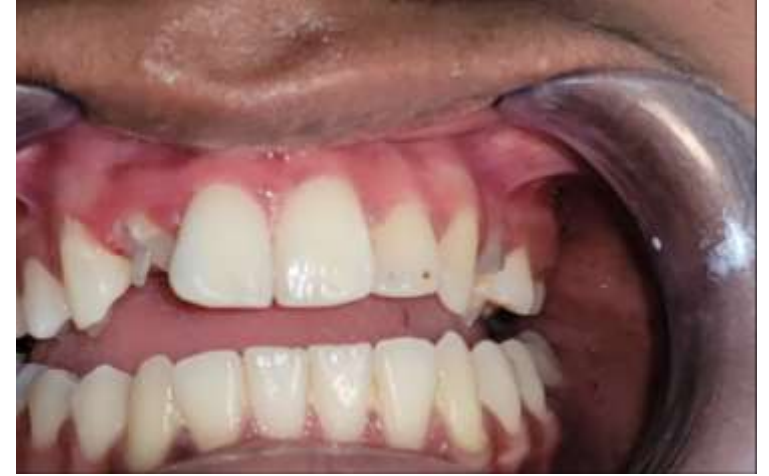PRE OP



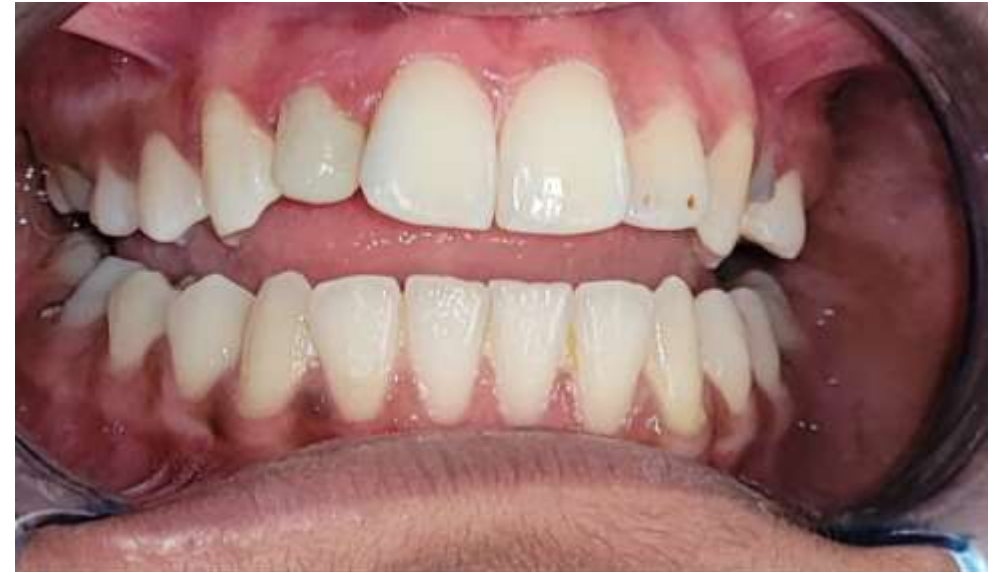IOPA



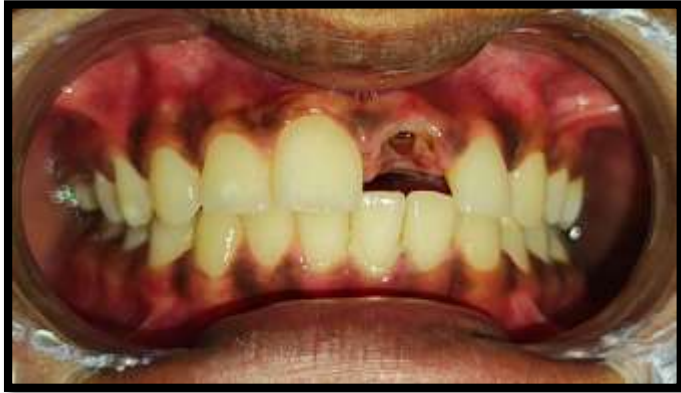FABRICATION OF POST



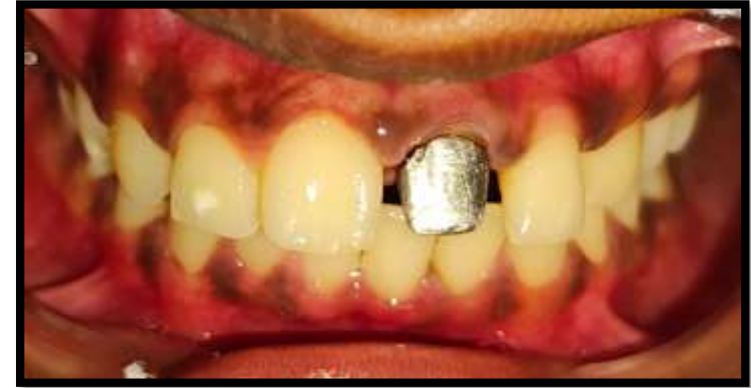POST OP



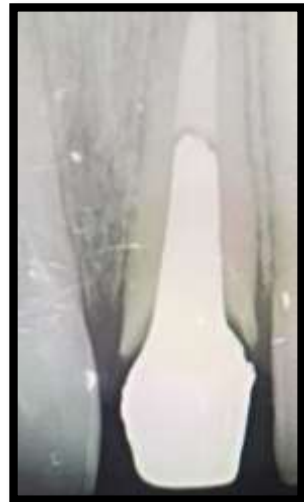Custom-Made Post And Core (Metal Post)



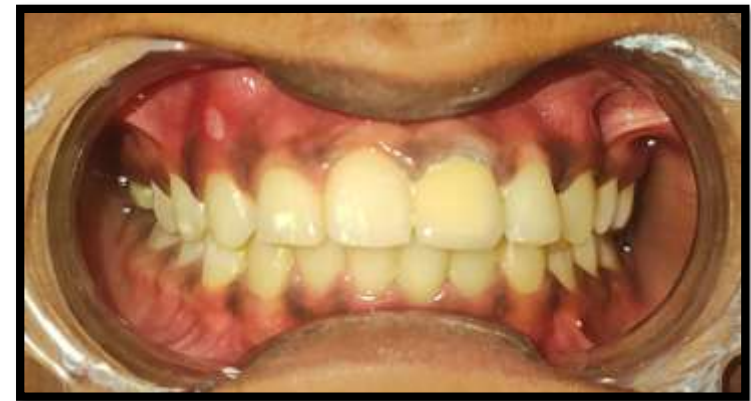Pre-op



Fabrication of metal post



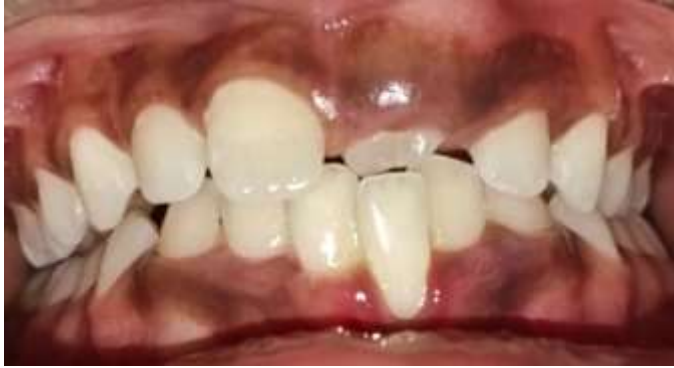IOP



Post- op

SURGICAL REMOVAL OF ODONTOME

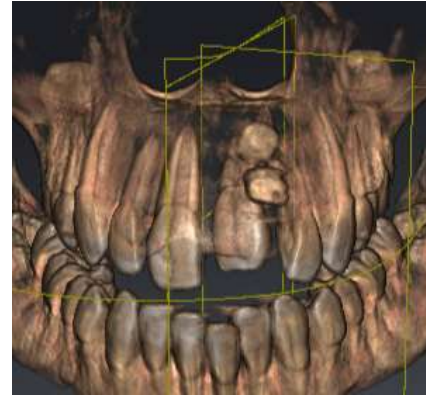
PRE-OP



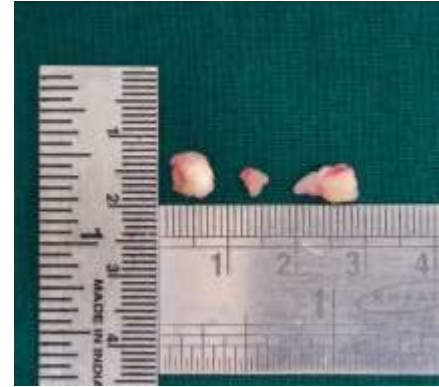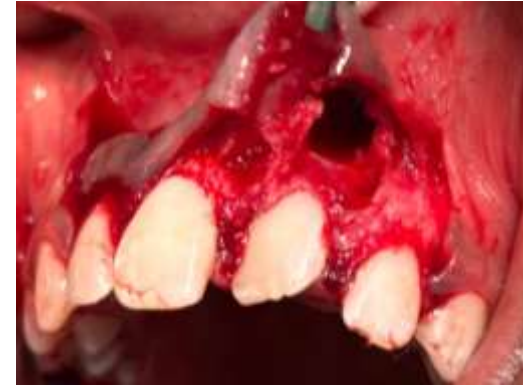IOPA



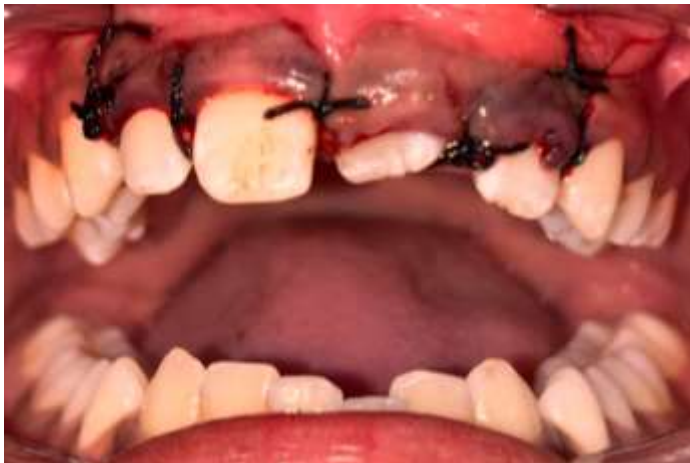CBCT



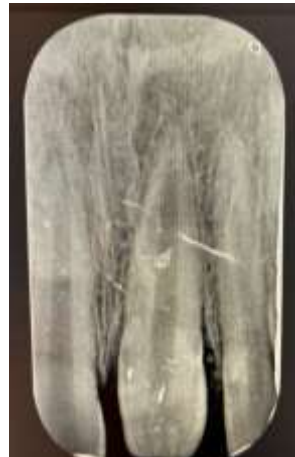**SURGICAL REMOVAL OF
COMPOUND ODONTOME**



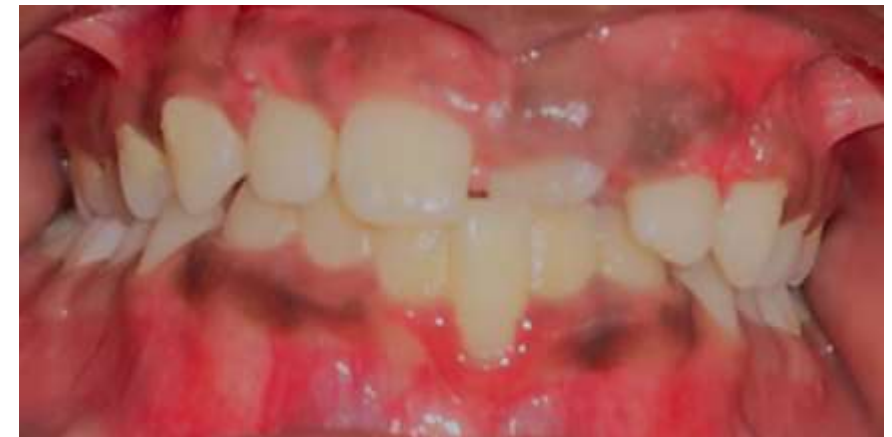POST- OP



POST- OP XRAY

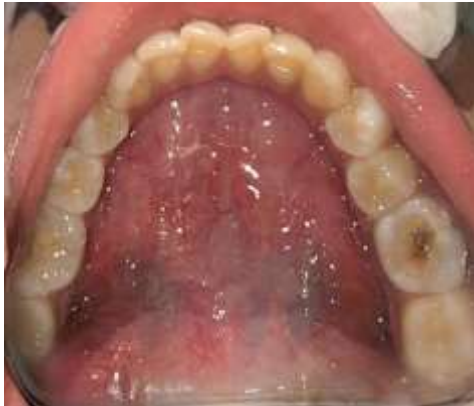

1 WEEK FOLLOW UP

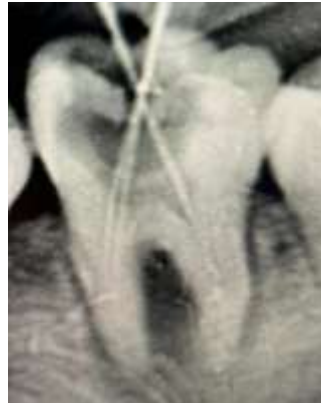

ENDODONTIC MANAGEMENT OF PULP STONE IN A MICRODONT TOOTH PATIENT WITH CEREBRAL PALSY

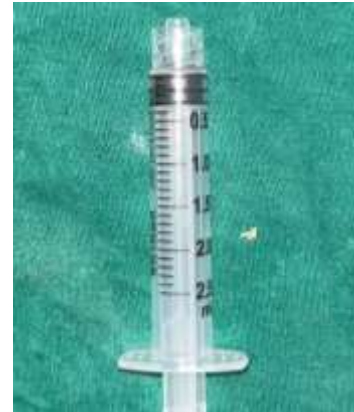PRE-OP



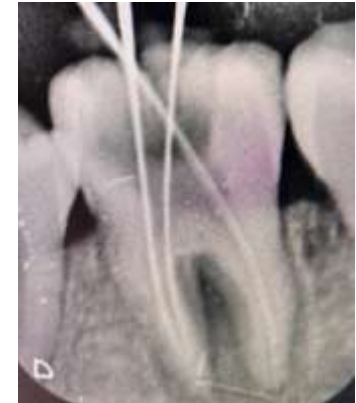IOPAR- SHORT WORKING LENGTH



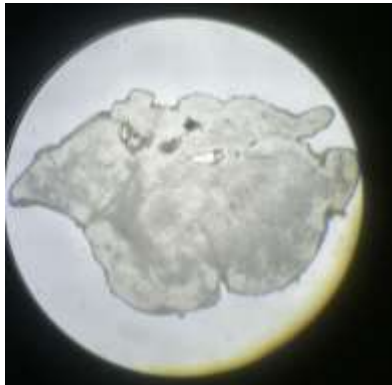PULP STONE



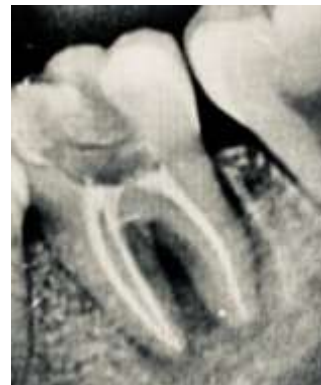IMPROVED WORKING LENGTH



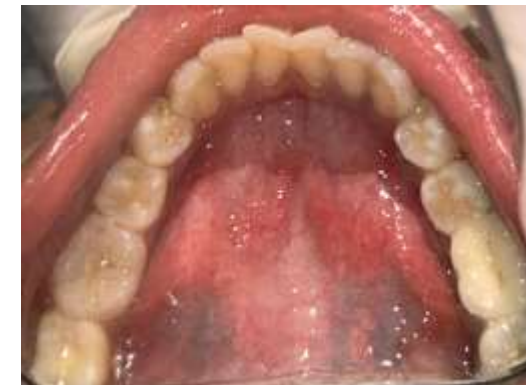HISTOPATHOLOGICAL EXAMINATION



OBTURATION

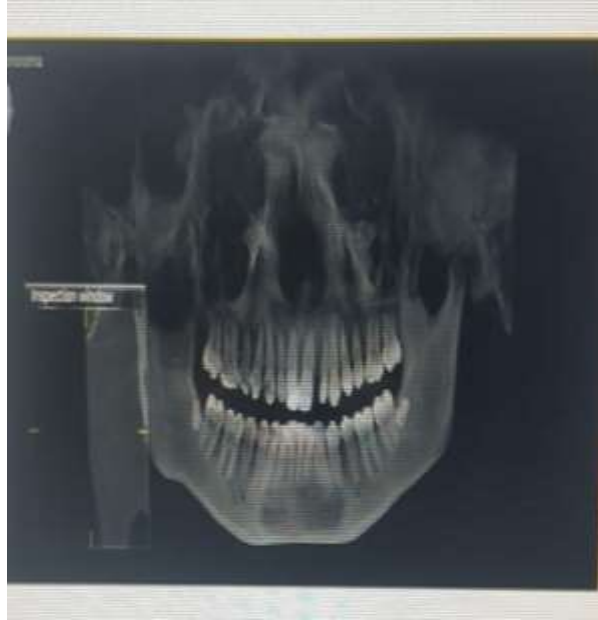
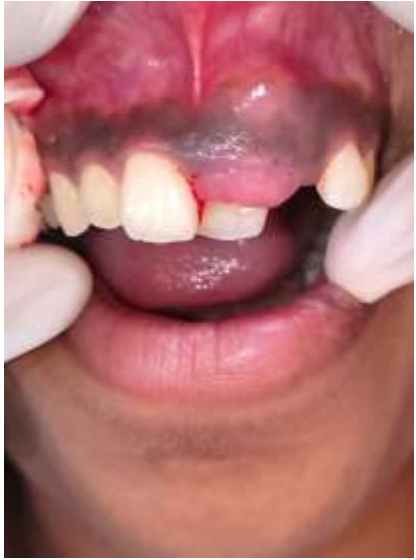
POST-OP PFM CROWN

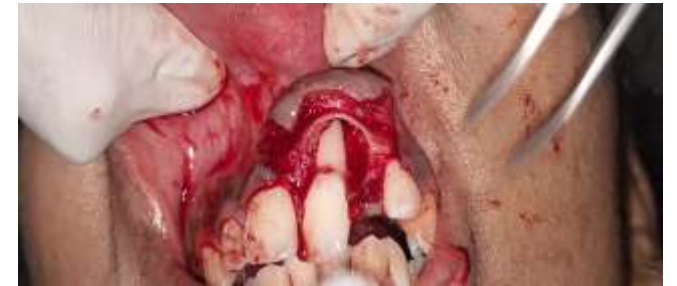
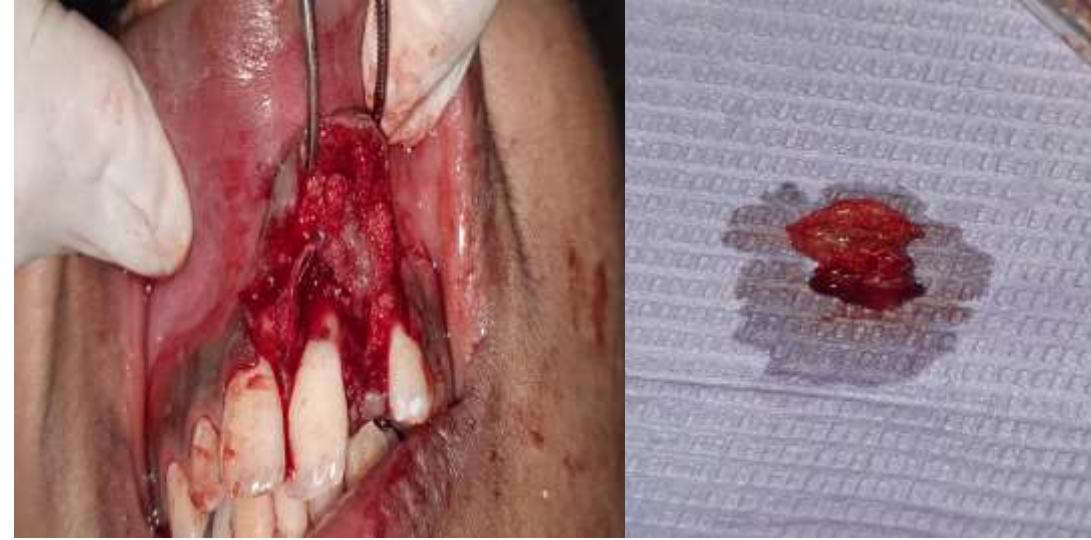
OSSIFYING FIBROMA WITH SCALPEL

PRE OPERATIVE IMAGE AND RADIOGRAPH



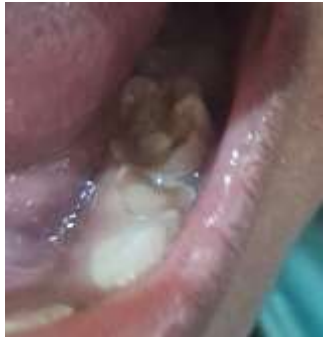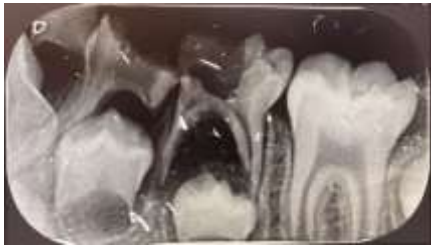POST OPERATIVE IMAGE AND COMPLETE EXICISION OF FIBROMA



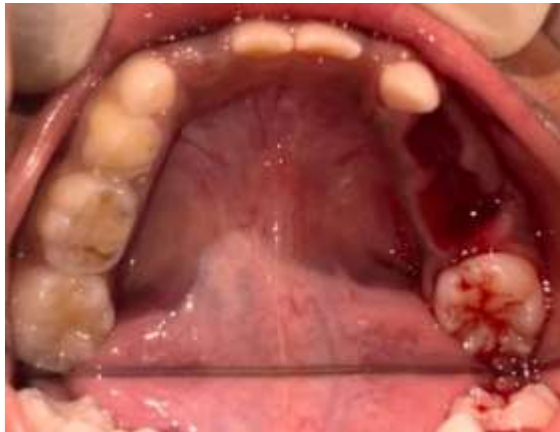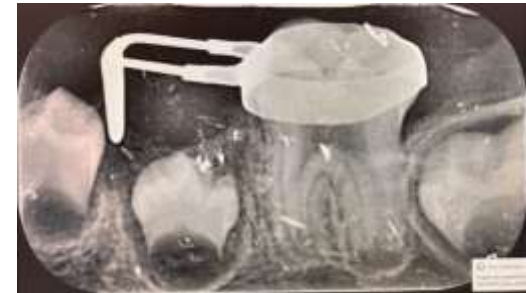MESIAL SHOE SPACE MAINTAINER

PRE OP

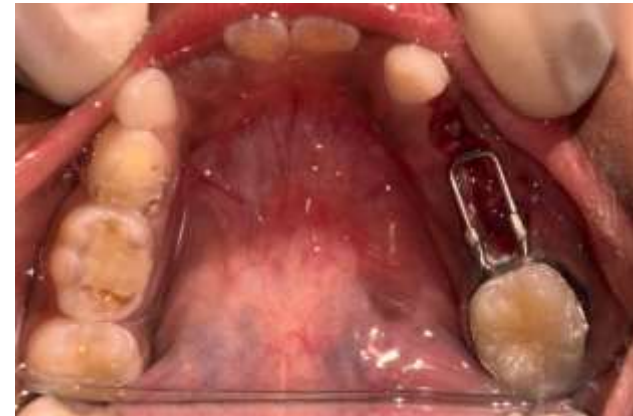grossly decayed 74,75



POST OP

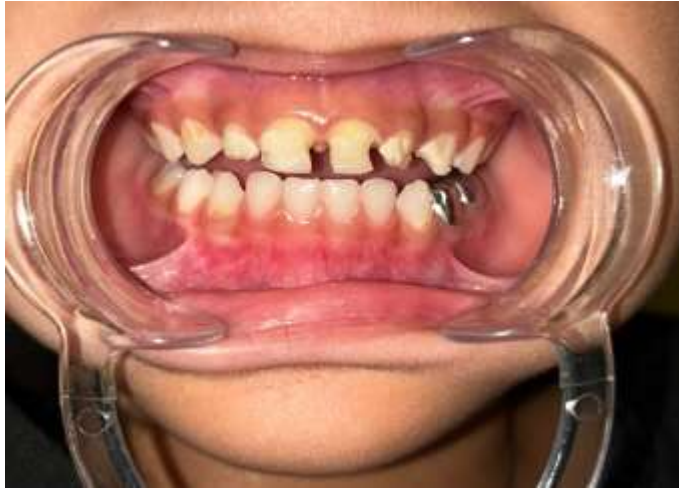

Immediate post extraction

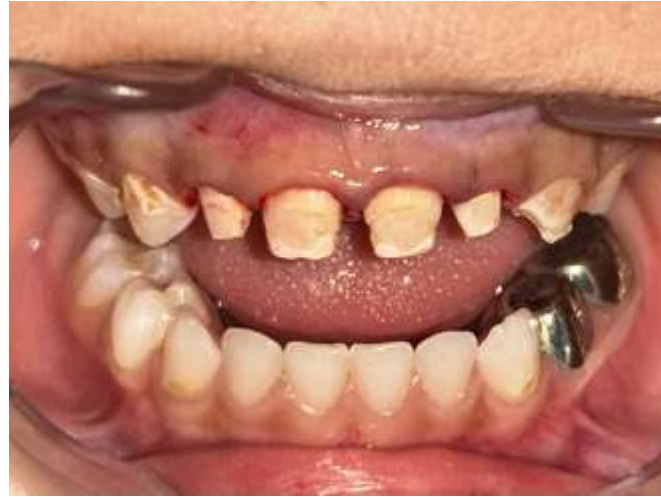

Mesial shoe space maintainer

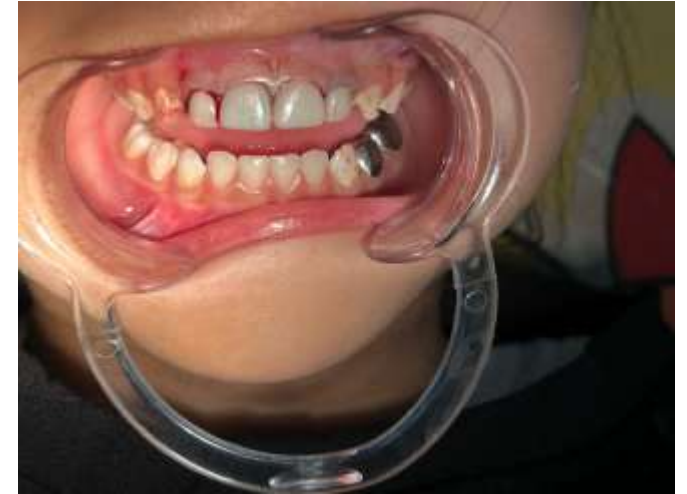Paediatric Zirconia crowns



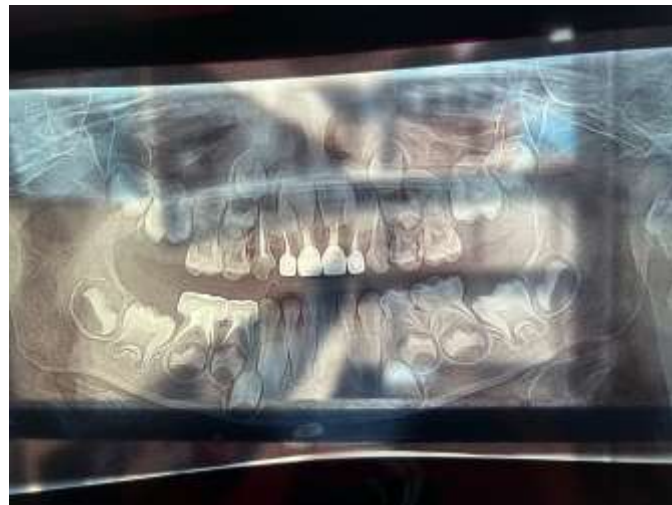Preop



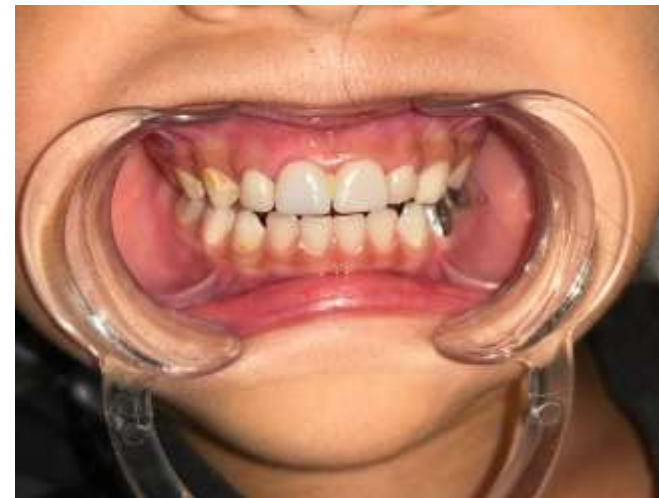Crown preparation



Crown placement



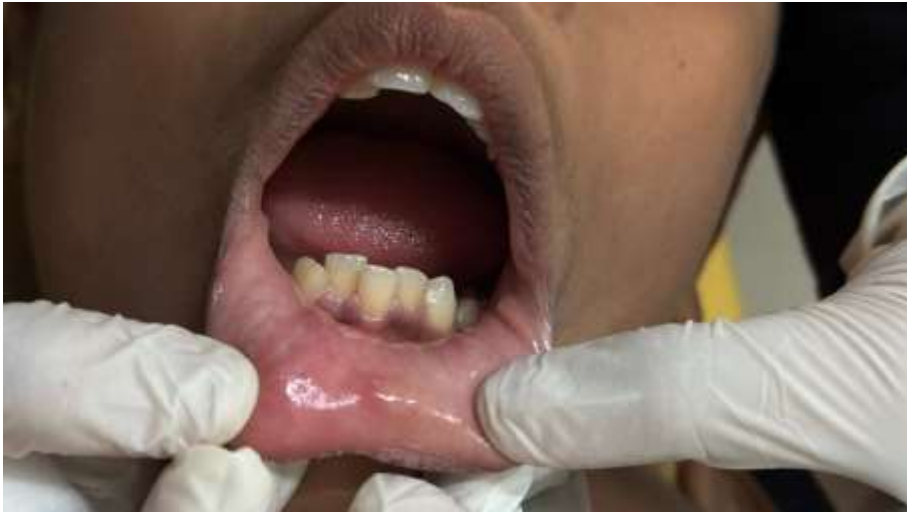Post treatment opg



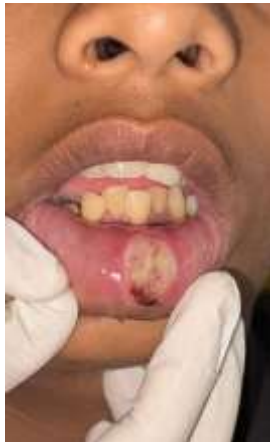2 weeks follow up

MUCOCELE EXCISION WITH LASER

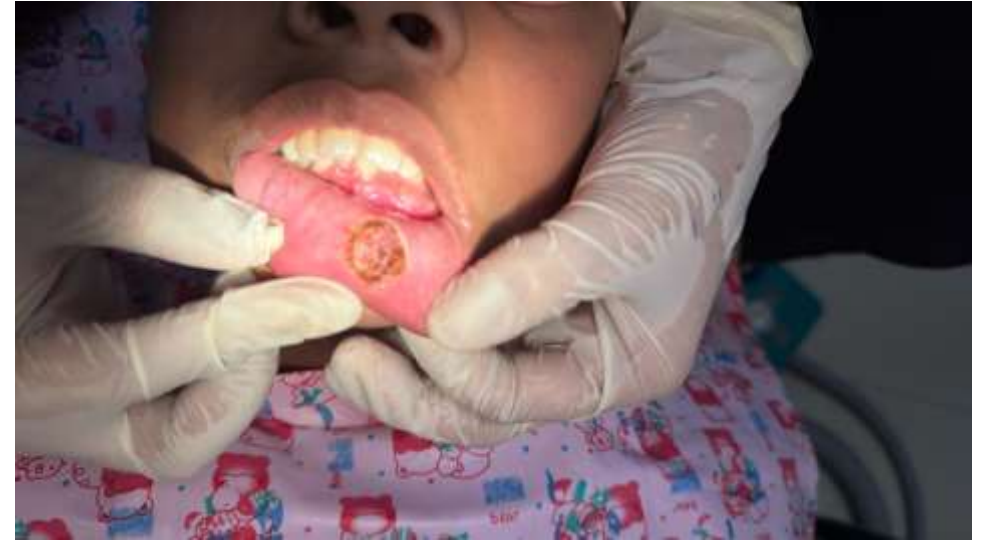PRE OP



FOLLOW UP AFTER ONE WEEK



POSTOP



FOLLOW UP AFTER 2 MONTHS

