



MATHRUSRI RAMABAI AMBEDKAR DENTAL COLLEGE & HOSPITAL

(Founded by : Ananda Social & Educational Trust)
ISO 9001:2015 CERTIFIED

Affiliated to Rajiv Gandhi University of Health Sciences
Recognised by Dental Council of India

1/36, Cline Road, Cooke Town, Bengaluru - 560 005
Ph: 080 - 2546 0747 www.mradc.in

INDEX

Sl. No	TABLE OF CONTENTS	Page No
1	Answer sheets	Page 2-17



P.R.P. P

PRINCIPAL

M.R. Ambedkar Dental College & Hospital
Bengaluru - 560 005





MATHRUSRI RAMABAI AMBEDKAR DENTAL COLLEGE & HOSPITAL

(Founded by : Ananda Social & Educational Trust)
ISO 9001:2015 CERTIFIED

Affiliated to Rajiv Gandhi University of Health Sciences
Recognised by Dental Council of India

1/36, Cline Road, Cooke Town, Bengaluru - 560 005
Ph: 080 - 2546 0747 www.mradc.in

 **M.R. AMBEDKAR DENTAL COLLEGE & HOSPITAL**
1/36, Cline Road, Cooke Town, Bengaluru - 560 005



✓ EXAMINATION of... JUNE 2023
I / II / III / FINAL INTERNAL ASSESSMENT ANSWER BOOK
THEORY / PRACTICAL

Dept. of..... Oral medicine

Booklet No. : 1 Reg. No. : 19D0928
Faculty : BDS Subject : OM
Year : IV year
Additional Sheet : —

37
50


FATEMA NAIM
Signature of the Candidate
Max. Marks.....

pathogenesis, CIF, investigation & management of pemphigus vulgaris. [5M]
Q2. Management of Oral lichen planus.
Q3. Staging of oral cancer
Q4. Internal disc disarrangement of TMJ.
Q5. Oral manifestation of HIV.
Q6. Sjogren's Syndrome.
Q7. Principle, advtg & deadvty of OPC. [2M]
Q8. Lip prints.
Q9. Antiviral drugs.
Q10. Biopsy
Q11) Plummer Visson syndrome.
Q12. Specialized imaging in dentistry



P.R.P.P

PRINCIPAL
M.R. Ambedkar Dental College & Hospital
Bengaluru - 560 005



MATHRUSRI RAMABAI AMBEDKAR DENTAL COLLEGE & HOSPITAL

(Founded by : Ananda Social & Educational Trust)
ISO 9001:2015 CERTIFIED

Affiliated to Rajiv Gandhi University of Health Sciences
Recognised by Dental Council of India

1/36, Cline Road, Cooke Town, Bengaluru - 560 005
Ph: 080 - 2546 0747
www.mradc.in

[2M] ORAL MEDICINE FINAL BDS EXAMINATION - 2023

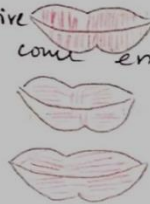[Q8] LIP PRINTS

Page 1

It is used as an aid in forensic odontology.

• Lip prints ^{Pattern} classification

- Vertical pattern cover entire lip.
- Vertical pattern don't cover entire lip
- Horizontal pattern
- Transverse pattern.
- Oblique patterns.



• In case of theft, abuse, domestic violence, rape cases lip prints of the perpetrator are left on the victim.

• These can be used to determine & identify the criminal.

- Disadvantage:
- They can change on burning, & physical trauma.
 - Not evident in all cases.
 - Misleading →

[Q9] Antiviral Drugs

① Acyclovir → 500 mg 1x1 for 5 days.

Indication -

- Herpes simplex.
- Herpes zoster.
- Bell's palsy.
- Cytomegalovirus Multiforme.
- Ramsay Hunt Syndrome.

② Valacyclovir [Pro drug of acyclovir] [3-4 times ↑ bioavailability]

Indication -

- HSV
- Herpes zoster.
- Bell's palsy.

③ Famciclovir.



P.R.P.P.P

PRINCIPAL

M.R. Ambedkar Dental College & Hospital
Bengaluru - 560 005



MATHRUSRI RAMABAI AMBEDKAR DENTAL COLLEGE & HOSPITAL

(Founded by : Ananda Social & Educational Trust)
ISO 9001:2015 CERTIFIED

Affiliated to Rajiv Gandhi University of Health Sciences
Recognised by Dental Council of India

1/36, Cline Road, Cooke Town, Bengaluru - 560 005
Ph: 080 - 2546 0747 www.mradc.in

④ **NNRTI** → non nucleotide reverse transcriptase inhibitors

→ lamivudine
→ zidovudine
→ didanosine
→ Ritonavir

Indication:
- HIV
- HAART → highly active anti retroviral therapy

⑤ **Foscarnet** → used for HSV in immuno compromised patient

⑩] **Biopsy** → removal of pathologic tissue for the purpose of diagnosis and investigation under microscope.

Types {
- excisional biopsy
- incisional biopsy

Excisional biopsy → removal of entire lesion & surrounding 1-2mm of normal tissue

Incisional biopsy → removal of small part of lesion & adjacent tissue.

Indications :
• Oral Cancer
• Metastatic lymph nodes [Malignancy]
• OSMF
• Leukoplakia
• Salivary Gland Tumors

⑪] **Plummer Vinson Syndrome**

Triad {
- Iron deficiency anemia
- Esophageal webs
- Dysphagia

Differential diagnosis:
• Oral submucous Fibrosis
• Scleroderma
• Amyloidosis

P.R.P.P.P

PRINCIPAL

M.R. Ambedkar Dental College & Hospital
Bengaluru - 560 005



MATHRUSRI RAMABAI AMBEDKAR DENTAL COLLEGE & HOSPITAL

(Founded by : Ananda Social & Educational Trust)
ISO 9001:2015 CERTIFIED

Affiliated to Rajiv Gandhi University of Health Sciences
Recognised by Dental Council of India

1/36, Cline Road, Cooke Town, Bengaluru - 560 005
Ph: 080 - 2546 0747 www.mradc.in

Q12. Specialized Imaging Techniques

① Extra oral Plain Radiographs

- Cephalogram
- Reverse Towne View
- Water's View
- Transcranial view
- Transpharyngeal view
- Transorbital view
- Jughandle's View

② Computed Tomography

③ Conventional Tomography

④ MRI

⑤ PET

⑥ Digital Radiography

⑦ Sialography

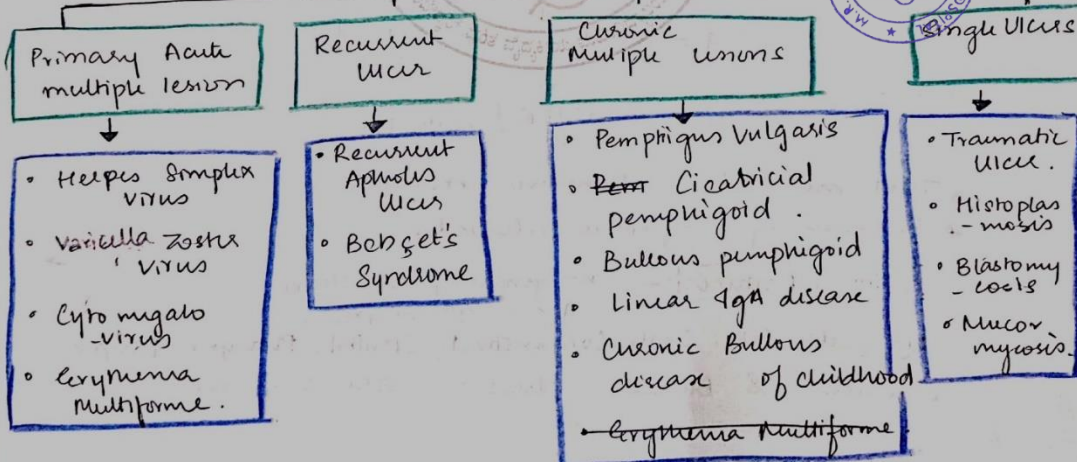
⑧ Scintigraphy

[10M]

Q1]

VESICULO-BULLOUS LESION

CLASSIFICATION



P.R.P.P.P

PRINCIPAL

M.R. Ambedkar Dental College & Hospital
Bengaluru - 560 005



MATHRUSRI RAMABAI AMBEDKAR DENTAL COLLEGE & HOSPITAL

(Founded by : Ananda Social & Educational Trust)
ISO 9001:2015 CERTIFIED

Affiliated to Rajiv Gandhi University of Health Sciences
Recognised by Dental Council of India

1/36, Cline Road, Cooke Town, Bengaluru - 560 005
Ph: 080 - 2546 0747
www.mradc.in

EMPHIGUS VULGARIS • pemphix → "blister"
• Chronic disease. Page 4

Etology:-
• It is an autoimmune blistering disease of the skin.

Pathogenesis:-

- Cell-cell adhesion due to desmosome.
- desmosomes attached by glue — Desmoglein 1 (Dsg1)
Desmoglein 3 (Dsg3)
- Auto antibodies circulate against Dsg1 & Dsg3

↓
Attack cell surface of keratinocyte.

↓
ACANTHOLYSIS

↓
Break down of cell adhesions

↓
Space between cells

↓
get filled with fluid

↓
BLISTER / VESICLE.

* Cell mediated autoimmune rxn
* Inflammatory cytokine released.

Clinical Features:- • no gender predilection
• Age - 40-60yrs.


General:- Site: Oral, Conjunctiva, Genital, Pharynx, Larynx.

- Vesicles & Bullae cluster all seen on skin
- If infected become pustules.

P.R.P.P

PRINCIPAL

M.R. Ambedkar Dental College & Hospital
Bengaluru - 560 005



MATHRUSRI RAMABAI AMBEDKAR DENTAL COLLEGE & HOSPITAL

(Founded by : Ananda Social & Educational Trust)
ISO 9001:2015 CERTIFIED

Affiliated to Rajiv Gandhi University of Health Sciences
Recognised by Dental Council of India

1/36, Cline Road, Cooke Town, Bengaluru - 560 005
Ph: 080 - 2546 0747

www.mradc.in

- Vesicles rupture to leave raw eroded surface ulcers. [Page 5]
- Ulcers are painful.
- **NIKOLSKY'S SIGN**: Oblique pressure application on area of skin adjacent to vesicles or on skin preceding formation of vesicle → sloughing off of adjacent tissue is seen.
- Pemphigus Vegetans → rare → only seen in 2%
 - F > M
 - Hallopeau pustules → rupture → vegetative raw ulcers.
 - Neuman's erosion
 - CEREBRIFORM TONGUE → elevation & depression in tongue seen like sulci & gyri.

Oral Manifestations:-

- Affects 50-70% of Oral Cavity.
- Vesicles & Bulla seen of lips, tongue, buccal labial mucosa, gingiva, hard palate, floor of mouth.
- Vesicle rupture
↓
raw eroded surface
ulcer.
- Also seen in larynx — hoarseness of voice
— difficulty in speech.
- Painful → Burning sensation
- Pharynx — difficulty in deglutition.
- Difficult in mastication.



P.R.P.P

PRINCIPAL

M.R. Ambedkar Dental College & Hospital
Bengaluru - 560 005



MATHRUSRI RAMABAI AMBEDKAR DENTAL COLLEGE & HOSPITAL

(Founded by : Ananda Social & Educational Trust)
ISO 9001:2015 CERTIFIED

Affiliated to Rajiv Gandhi University of Health Sciences
Recognised by Dental Council of India

1/36, Cline Road, Cooke Town, Bengaluru - 560 005
Ph: 080 - 2546 0747 www.mradc.in

Investigations:-

• Biopsy → Presence of TZANCK CELLS

↓

Multiple cluster of cells seen in fluid of vesicle having

- Swollen nuclei
- ~~eco~~ hyperchromatic stained nuclei

• Direct Immunofluorescence

• Serological Tests :

- ① ANA
- ② Anti-ds DNA
- ③ Anti-smith
- ④ Anti RO
- ⑤ Anti LA
- ⑥ Direct Coombs Test

DD:- Pemphigoid [Cicatricial, Bullous], Systemic lupus erythematosus, Erythema multiforme, Bullous lichen planus

Management:-

Pain Control:-

- 2% Lignocaine
- Diclofenac HCl
- Analgesics — Ibuprofen, Diclofenac

Supportive Therapy:-

- Ice chips
- Bland diet
- Hydration
- Nutritional

Definitive Therapy:-

Topical Corticosteroids:

- Triamcinolone acetonide → 0.01%

P.R.P.P.P

PRINCIPAL
M.R. Ambedkar Dental College & Hospital
Bengaluru - 560 005



MATHRUSRI RAMABAI AMBEDKAR DENTAL COLLEGE & HOSPITAL

(Founded by : Ananda Social & Educational Trust)
ISO 9001:2015 CERTIFIED

Affiliated to Rajiv Gandhi University of Health Sciences
Recognised by Dental Council of India

1/36, Cline Road, Cooke Town, Bengaluru - 560 005
Ph: 080 - 2546 0747 www.mradc.in

• Clobesol propionate .

Systemic Steroids :

- Prednisolone 30-40 mg .

Immuno suppressive drugs :

- Methotrexate
- Azathioprine .
- Cyclosporine .

Immuno modulatory drug : Mycoplumolate . Mofetil .

Mono clonal antibody : Belimumab

Q2 . Lichen Planus .

Management :-

① Treat etiology :-

- Remove predisposing factor / irritant .
- Nutritional supplements .


②

Lichen Planus

```
graph TD
    LP[Lichen Planus] --> AC[Associated with Candida]
    LP --> NAC[Not associated with candida]
    AC --> AM[Mild]
    AC --> AS[Severe]
    NAC --> NM[Mild]
    NAC --> NS[Severe]
    AM --> AMT[Topical steroids & topical antifungal drugs]
    AS --> ASAT[Systemic steroids & systemic antifungal drugs]
    NM --> NMT[Topical steroids]
    NS --> NST[Systemic steroids]
```

P.R.P.P

PRINCIPAL
M.R. Ambedkar Dental College & Hospital
Bengaluru - 560 005

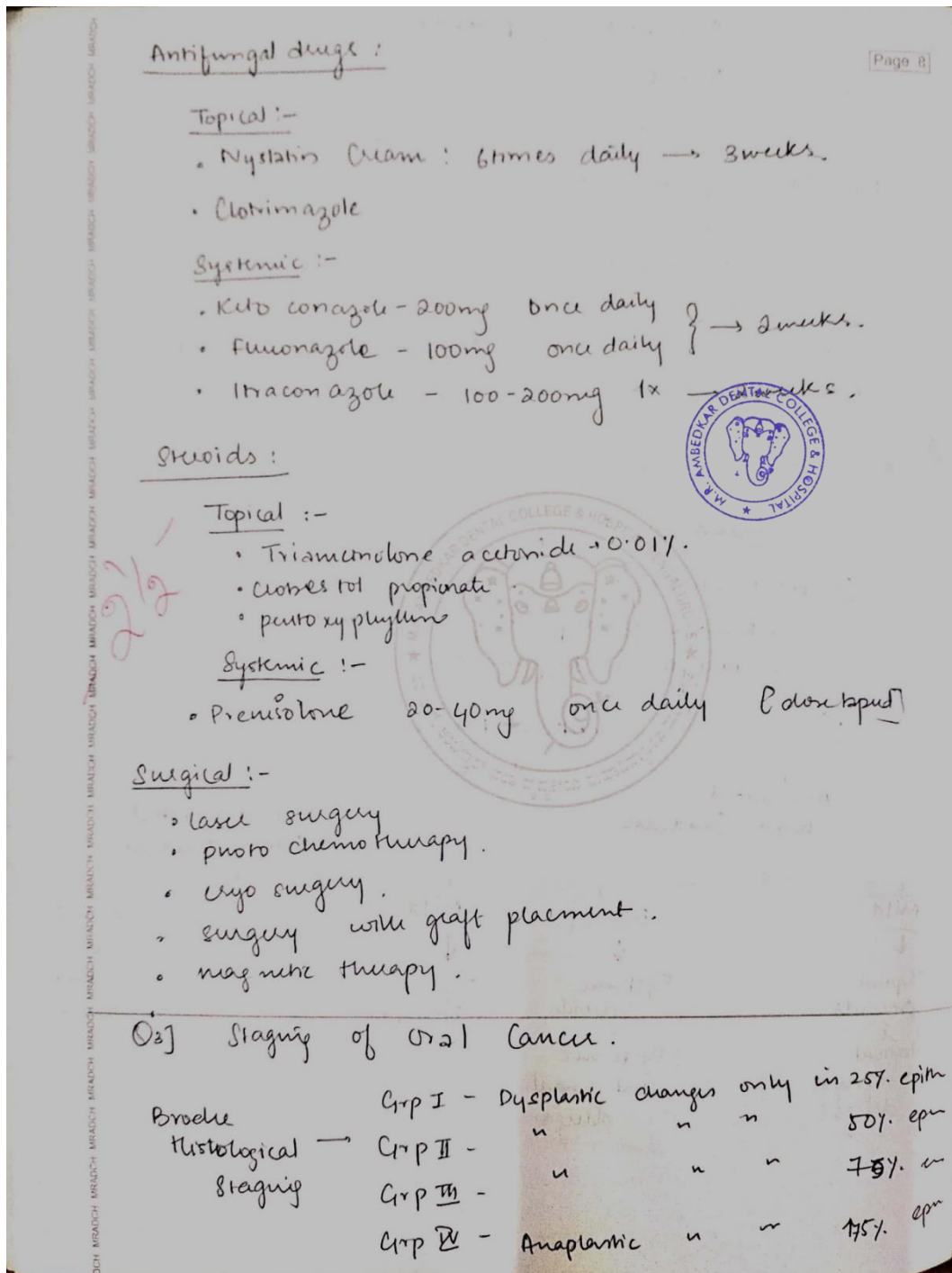


MATHRUSRI RAMABAI AMBEDKAR DENTAL COLLEGE & HOSPITAL

(Founded by : Ananda Social & Educational Trust)
ISO 9001:2015 CERTIFIED

Affiliated to Rajiv Gandhi University of Health Sciences
Recognised by Dental Council of India

1/36, Cline Road, Cooke Town, Bengaluru - 560 005
Ph: 080 - 2546 0747 www.mradc.in





MATHRUSRI RAMABAI AMBEDKAR DENTAL COLLEGE & HOSPITAL

(Founded by : Ananda Social & Educational Trust)
ISO 9001:2015 CERTIFIED

Affiliated to Rajiv Gandhi University of Health Sciences
Recognised by Dental Council of India

1/36, Cline Road, Cooke Town, Bengaluru - 560 005

TNM Staging

Page 9

T - tumor.
N - Node.
M - Metastasis.

T₀ - No evidence of tumor.

T_x - No tumor present /

T₁ - Size of tumor ≤ 2 cm.

T₂ - " $\approx 2-4$ cm

T₃ - " ≥ 4 cm.

M_x - Metastasis not present

M₀ - No evidence of metastasis

M₁ - Metastasis present.

M_x - Absent

N₀ - No evidence of lymph node involvement.

N₁ - Unilateral LN involved size ≤ 3 mm - 4 mm

N₂ - ~~Unilateral~~ Bilateral LN involved size ≤ 3 mm - 4 mm

N₃ - Unilateral LN involved size ≥ 6 mm

N₄ - ~~Unilateral~~ Bilateral LN involvement size ≥ 6 mm.

Q4] Internal derangement.

• It is a disease caused due to displacement of articular disc in TMJ.

- CIF:
- Clicking sound
 - Painful
 - Restricted opening of mouth.
 - Jaw opening painful.

P.R.P.P.P

PRINCIPAL

M.R. Ambedkar Dental College & Hospital
Bengaluru - 560 005



MATHRUSRI RAMABAI AMBEDKAR DENTAL COLLEGE & HOSPITAL

(Founded by : Ananda Social & Educational Trust)
ISO 9001:2015 CERTIFIED

Affiliated to Rajiv Gandhi University of Health Sciences
Recognised by Dental Council of India

1/36, Cline Road, Cooke Town, Bengaluru - 560 005
Ph: 080 - 2546 0747
www.mradc.in

Page 10

- Etiology :
 - Trauma
 - Malocclusion
 - Parafunctional habits → grinding, bruxism
 - Psychological
- Inv :
 - OPC
- Treatment :
 - Surgical Approach
 - treat malocclusion → ortho
 - Night guards
 - Polymeric counselling

22

Q] Oral Manifestation of Aids.

Bacterial :

- Tuberculosis
- Leprosy
- Syphilis
- Mycobacterium Avium
- Diphtheria

Viral :


- Oral hairy leukoplakia
- Epstein bar virus -
- ANUG
- NUP
- Herpes Simplex
- Herpes Zoster

Fungal :

- Mucormycosis
- Candidiasis
- Histoplasmosis

P.R.P.P

PRINCIPAL
M.R. Ambedkar Dental College & Hospital
Bengaluru - 560 005



MATHRUSRI RAMABAI AMBEDKAR DENTAL COLLEGE & HOSPITAL

(Founded by : Ananda Social & Educational Trust)
ISO 9001:2015 CERTIFIED

Affiliated to Rajiv Gandhi University of Health Sciences
Recognised by Dental Council of India

1/36, Cline Road, Cooke Town, Bengaluru - 560 005
Ph: 080 - 2546 0747
www.mradc.in

Parasitic : toxoplasmosis.

Oral lesions:

- 1) Neoplasm : Squamous cell carcinoma
- Kaposi Sarcoma.
 - Hodgkin Lymphoma.
 - Non - Hodgkin Lymphoma.

- 2) Lesion : Oral hairy leukoplakia.
- ANUG, NUP.
 - ~~Herpes~~ Herpes Simplex.
 - Oral Candidiasis.
 - Herpangina.
 - Periodontitis.
 - Carcenum Ovis.

- Oral hairy leukoplakia:
- Occurs in association with EBV and HIV.
 - White plaque present of lateral border of tongue.
 - Treat : Acyclovir, Lamivudine.
- Kaposi Sarcoma
- Vascular neoplasm associated with HIV.
- ANUG / NUP
- Necrotizing disease of periodontal & gingival tissue.
 - Deep punched out crater like ulcers with yellow pseudo membrane.
 - Painful condition.
- Periodontitis
- Seen commonly in Aids pt.
 - Loss of attachment & bone.
- Herpes in immunocompromised present as vesicles & bulla repete erosions / ulcers. Very painful.

Page 11



P.R.P. P

PRINCIPAL
M.R. Ambedkar Dental College & Hospital
Bengaluru - 560 005



MATHRUSRI RAMABAI AMBEDKAR DENTAL COLLEGE & HOSPITAL

(Founded by : Ananda Social & Educational Trust)
ISO 9001:2015 CERTIFIED

Affiliated to Rajiv Gandhi University of Health Sciences
Recognised by Dental Council of India

1/36, Cline Road, Cooke Town, Bengaluru - 560 005
Ph: 080 - 2546 0747
www.mradc.in

Treat : Fosarnet .

→ Chronic Atrophic Candidiasis

- Leukoplakia, Leukoplakia, nodules of hard palate .

→ Acute Pseudomembranous Candidiasis

- Yellowish white mass when scraped there is a painful ~~red~~ red leukoplakia below .

→ Thrush

- Vesicles → Painful / Choking feeling of throat with swallowing
- Occurs in 50% of HIV pt who've had zoster infection .

Q6] Sjogren's Syndrome .

→ Autoimmune disorder of Salivary Gland .

→ Commonly affects major SG → Parotid Gland .

Types

- 1° Sjogren Syndrome : Keratoconjunctivitis sicca + xerostomia
- 2° Sjogren Syndrome : Keratoconjunctivitis sicca + xerostomia + autoimmune disease → Rheumatoid Arthritis / SLE / Scleroderma .

→ Etiology -

- Genetic
- Autoimmune .
- EBV, CMV .
- Unknown .

Page 12

P.R.P. P

PRINCIPAL

M.R. Ambedkar Dental College & Hospital
Bengaluru - 560 005



MATHRUSRI RAMABAI AMBEDKAR DENTAL COLLEGE & HOSPITAL

(Founded by : Ananda Social & Educational Trust)
ISO 9001:2015 CERTIFIED

Affiliated to Rajiv Gandhi University of Health Sciences
Recognised by Dental Council of India

1/36, Cline Road, Cooke Town, Bengaluru - 560 005
Ph: 080 - 2546 0747
www.mradc.in

→ CIF :- Page 13

- Decrease in saliva → xerostomia
↓
Dry mouth

Causes Periodontitis Malocclusion

- ↑ Chance of candidal infections .
- & Dryness & Burning of eyes .
- Burning sensation of oral mucosa .
- Glossodynia .
- Inflammation of eyes & redness .

→ Investigations :

- ANA → anti nuclear antibody
- Anti ds-DNA → anti double stranded DNA
- Anti-RO }
- Anti-La } → Present .
- Sialography :
 - Cherry Blossom Appearance
 - Snow storm appearance
- Hyper gamma globulinemia .
- Altered Albumin Globulin ratio .

→ Treatment :

- Artificial tears .
- Artificial saliva .
- Lemon & citrus food .
- Corticosteroids → systemic → Prednisolone 20-40mg .

P.R.P.P
PRINCIPAL
M.R. Ambedkar Dental College & Hospital
Bengaluru - 560 005



MATHRUSRI RAMABAI AMBEDKAR DENTAL COLLEGE & HOSPITAL

(Founded by : Ananda Social & Educational Trust)
ISO 9001:2015 CERTIFIED

Affiliated to Rajiv Gandhi University of Health Sciences
Recognised by Dental Council of India

1/36, Cline Road, Cooke Town, Bengaluru - 560 005
Ph: 080 - 2546 0747 www.mradc.in

Q1] Ortho pantomograph . [Page 14]

Principle :-


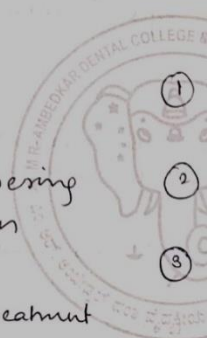
- tomographic image is captured of both jaws
- The film moves with the x-ray beam at constant speed in a panoramic manner.
- Captures all the dentoalveolar structures, entire mandible.

Advantage :-

- 1) Captures all dentition.
- 2) Useful in assessing bone loss in periodontitis.
- 3) ^{Aids in} Orthodontic treatment planning.
- 4) Aids in implant placement.
- 5) Shows eruption status in mixed dentition.
- 6) Can be used to see proximity of impacted 3rd molar to inferior alveolar canal.
- 7) Cyst, tumors diagnosis.

Disadvantage :-

- 1) Increased X-ray exposure.
- 2) Image produced is not of good details.
- 3) Structures like lamina dura not easily visualized.
- 4) Fine details absent.
- 5) Image distorted.






MATHRUSRI RAMABAI AMBEDKAR DENTAL COLLEGE & HOSPITAL

(Founded by : Ananda Social & Educational Trust)
ISO 9001:2015 CERTIFIED

Affiliated to Rajiv Gandhi University of Health Sciences
Recognised by Dental Council of India

1/36, Cline Road, Cooke Town, Bengaluru - 560 005
Ph: 080 - 2546 0747 www.mradc.in



P.R.P. P

PRINCIPAL

M.R. Ambedkar Dental College & Hospital
Bengaluru - 560 005